

The Euroson PoC-US School 3rd Edition


The Point of Care Ultrasonography in
Family Medicine and Ambulatory Healthcare

Vienna, Austria
09th-10th September,
2022

ABSTRACTS BOOK



EACCME®
European Accreditation Council
for Continuing Medical Education



An EUVEKUS® Event

EACCME®
Accreditation of event
reference #LEE22-00379

Euroson PoC-US School,


3rd Edition

The Point of Care Ultrasonography in Family
Medicine and Ambulatory Healthcare

Vienna, Austria
Sept. 09-10, 2022



EACCME®
European Accreditation Council
for Continuing Medical Education



© 2022 EUVEKUS

All rights reserved. No part of this publication may be reproduced, stored in an automated database, or made public, in any form or by any means whatsoever, whether electronic, mechanical, using photocopies, recording or any other means, without the prior permission of the publisher.

Although great care has been taken to maintain the accuracy of information contained in this publication, neither the publisher nor the editorial team assume any responsibility for any other damages that may arise from any mistakes or omissions that may occur in this publication. However, we are open to any suggestions that may help to improve the content.

Editor-in-Chief: Dr. Mihai Jacob


This book is available on the EUROSON POCUS SCHOOL website: <https://eurosonpocus.com/>

Table of Contents:

1.Foreword.....	3
POCUS - THE MODERN TOOL OF THE FUTURE CLINICAL-ULTRASOUND EXAMINATION THAT COULD APPLY TO THE FUTURE EUROPEAN AMBULATORY AND PRIMARY HEALTHCARE, Mihai Jacob	3
2.Conference Venue.....	4
Universitätszahnklinik Wien	4
3.EUVEKUS Organization.....	5
4.CONFERENCE AGENDA.....	6
Programme	6
Friday, 09 September 2022.....	6
Saturday, 10 September 2022.....	7
5.Abstracts.....	9
6.RAPID DETECTION OF NAFLD AND ITS EVOLUTIONARY STAGES TOWARD CIRRHOSIS IN THE TARGETED POPULATION THROUGH MULTIMODAL LIVER ULTRASONOGRAPHIC SCREENING (MLUS) AND ARTIFICIAL INTELLIGENCE WITH FIBROSIS RISK STRATIFICATION BY FAMILY PHYSICIANS. Mihai Jacob.....	9
7.CLINICAL-ULTRASOUND-SCREENING OF CHRONIC KIDNEY DISEASE(CKD) IN HIGH-RISK PATIENTS WITH KNOWN CARDIO-RENAL-METABOLIC DISORDERS AND THE CORRELATIONS BETWEEN CLINICAL METHODS OF KDIGO ASSESSMENT OF RENAL FUNCTION AND RENAL MULTIMODAL ULTRASOUND BY FAMILY PHYSICIANS. Mihai Jacob, Andrei Iacob.....	10
8.FEPO-THE FAST EXAMINATION METHOD FOR THE PARENCHYMAL ORGANS FOR EARLY DIAGNOSIS OF FOCAL LESIONS CORRELATED WITH A MULTIMODAL ULTRASOUND SCREENING AT THE PRIMARY HEALTHCARE LEVEL TO HIGH-RISK POPULATIONS. Mihai Iacob	11
9.RESULTS OF THE THYROSREEN CROSS-BORDER PROJECT. THE RISK STRATIFICATIONS OF THYROID PATHOLOGY. THE USE OF ARTIFICIAL INTELLIGENCE IN THYROID ULTRASOUND SCREENING IN PRIMARY HEALTHCARE. Mihai Iacob.....	12
10.CURRENT GUIDELINE PROJECTS OF EFSUMB AND THE ROLE OF POCUS. Christian Jenssen	13
11.SIMPLE US-GUIDED BEDSIDE INTERVENTIONS. Christian Jenssen	14
12.THE NEW CONCEPT OF THE CLINICAL-ULTRASOUND EXAMINATION IN CURRENT MEDICAL PRACTICE. Shlomo Vinker.....	15
13.INDETERMINATE TESTICULAR LESIONS: ROLE OF MULTIPARAMETRIC ULTRASOUND. Paul S. Sidhu	16
14.ADVANCES IN LIVER IMAGING: B-MODE TO MULTIPARAMETRIC ULTRASOUND. Paul S. Sidhu	16
15.THE USE OF MAMMARY ECHOGRAPHY IN THE DETECTION OF BREAST CANCER UNDER ONE CENTIMETRE IN SIZE. Dominique AMY	17
16.MULTIPARAMETRIC ULTRASOUND IN HEPATOLOGY. Ioan Sporea	19
17.TRANSABDOMINAL ULTRASOUND OF DIGESTIVE TUBE (GIUS). Ioan Sporea	20
18.THE ROLE OF ARTIFICIAL INTELLIGENCE IN THE COMPLEX EVALUATION OF PATIENTS WITH LIVER STEATOSIS. Adrian Saftolu.....	22
19.FOCUS (FOCUSED CARDIAC ULTRASOUND) AND BASIC CARDIAC ULTRASOUND FOR NON-CARDIOLOGISTS. Gergely Agoston	23
20.SONOGRAPHY IN EMERGENCY AMBULANCE SERVICE. Peter Sigmund.....	24
21.POCUS (POINT OF CARE SONOGRAPHY) IN GENERAL MEDICINE. Peter Sigmund	24
22.SYNDROME-FOCUSED ULTRASONOGRAPHY. Mateusz Kosiak.....	25
23.THORACIC ULTRASOUND. Mateusz Kosiak.....	25
24.INTRODUCTION TO THYROID CLINICAL ULTRASOUND. Dana Stoian	26
25.INTRODUCTION TO DUCTAL AND CONVENTIONAL BREAST CLINICAL ULTRASOUND. Dana Stoian	27
26.INTRODUCTION TO ULTRASOUND-BASED ELASTOGRAPHY. Vito Cantisani.....	28
27.STRAIN ELASTOGRAPHY AS A USEFUL TOOL IN DAILY PRACTICE. Vito Cantisani.....	29
28.AI ROLE IN OBTAINING CARDIAC ASSESSMENT PARAMETERS: A CASE DEMONSTRATION DURING A ROUTINE VISIT TO THE PRIMARY CARE CLINIC. Vaigast S., Binenbaum M., Evron, I, Polliack G., Zicherman Y., Chadi B Triso Technologies, Ishi,Israel	30
29.ULTRASONOGRAPHY AND MEDICAL IMAGING MODULE FROM THE ROMANIAN TRAINING CURRICULUM IN THE SPECIALTY OF FAMILY MEDICINE. Mihai IACOB, Viorela Enachescu, Radu Badea.....	31
30.FEEDBACK QUESTIONNAIRE. EACCME participants evaluation form	32



The Point of Care Ultrasonography in Family Medicine
- updates and perspectives 3rd Edition.
9-10 SEPTEMBER, 2022
VIENNA, AUSTRIA
Medizinische Universität/Universitätsklinik Wien
A-1090 Vienna, Sensengasse 2a.



POCUS - THE MODERN TOOL OF THE FUTURE CLINICAL-ULTRASOUND EXAMINATION THAT COULD APPLY TO THE FUTURE EUROPEAN AMBULATORY AND PRIMARY HEALTHCARE.

Dear Colleagues,

The Point of Care Ultrasonography performed by the clinician at the site of patient care, both in the medical office or at home, is an important tool to guide the case management for the early diagnosis and increase diagnostic accuracy. It represents an extension and complement to the clinical examination of the physician to achieve an accurate positive and differential diagnosis. POC-US is now an investigation in development, which can complement the physical examination of family doctors and could guide the case management of bedridden patients.

We need training and quality standards to ensure that this will be done in a way with positive benefits for our patients, being useful, to the implementation of ultrasound standards and practice guidelines at the primary care level.

It involves personal contact between doctor and patient at the "bedside", it is a fast real-time method, repetitive, cheap, and harmless but dependent on the experience and expertise of the examiner.

A new opportunity for PoC-US represents the application in primary care of the medical projects related to „telemedicine“ connections among specialists and family doctors for enhanced patient management. The Educational Needs of GPs on the new methods and technologies are increasing, but the resources and infrastructure are limited now.

It is thus necessary, the collaboration among the family physicians trainers, or academics, on the one hand, and the other specialty physicians in the preparation and continuing medical education in family medicine. Early diagnosis can help to save many patients in primary care based on notions of good clinical practice. Therefore, we will involve to inform family physicians about the latest diagnostic and treatment protocols in clinical ultrasound.

The workshop will include an interactive presentation and practice examples with ultrasound movies, role plays and a short Hands-On Session, and we will debate lectures and practical demonstrations by the interpretation of various ultrasound images of some applications of the Point of Care Ultrasonography in Family Medicine. Participants will enter the ultrasound semiology data on various smart software based on artificial intelligence (AI), that we will present, as a tool of support for unqualified doctors in PoC-US. These Smart Ultrasound Software are designed by us in the form of a modern diagnostic algorithm and represent a premiere in the PoC-US field.

Participants will receive practical information and tips on new Point of Care Ultrasonography applications in family practice.

The participants of this POCUS workshop will be educated according to the latest EFSUMB guidelines in the field of clinical ultrasonography.

This instrument through which the doctor can visualize most parenchymal organs(ultrasound inspection), or could see, hear and quantify blood circulation and pulsations, the direction of blood flow using the Doppler technique(ultrasound auscultation), or perform electronic palpation using the elastography technique to determine the tissue stiffness.

All these US techniques could be used in the current medical practice to increase the accuracy of positive and differential diagnoses.

We will present the results of a European Survey carried out by us about POCUS applications in Family Medicine, but also we will present some applications that are already included in the currently existing European Family Medicine Residency Training Curriculum. Finally, as a European Ultrasound Working Group in Ambulatory and Primary Healthcare - EUVEKUS we will work together with EFSUMB and WONCA Europe to the development of some future POCUS guidelines.

With best wishes,

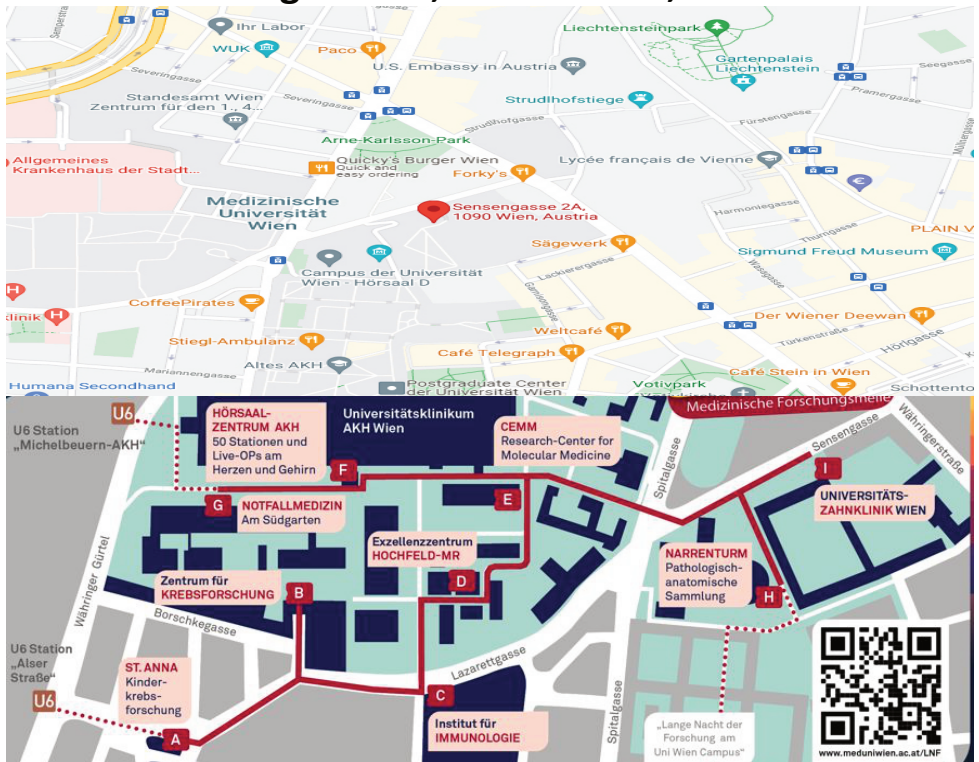**Dr. Mihai Iacob, MD, Senior Medical Expert,
EUVEKUS President, Local Keynote Speaker**



CONFERENCE VENUE



I. Universitätszahnklinik Wien Sensengasse 2A, 1090 Vienna, Austria



EUEKUS ORGANIZATION

EUEKUS - Europäische Vereinigung für die Entwicklung von Klinischen Ultraschalluntersuchungen im Ambulanten Gesundheitswesen

EADUS/AEDUS - European Association for the Development of Clinical Ultrasonography in Ambulatory Health Care (Outpatient Health Care)

The governing body of EUEKUS is the **Board of Directors** made up of the following founding members:

- I. **President - Dr. Mihai IACOB**
- II. **Member Board** - Andrea Eugenia IACOB
- III. **Member Board** - Elvis STOICA
- IV. **Secretary** - Mariane STOICA

HONORARY MEMBERS are the members who, through their personality, adhere to the association and morally and/or materially support the maintenance and development of, or bring, or are able to bring special services to its association and activity.

EUEKUS has the following **honorary members**:

- I. **Dr. Ilse Hellemann** : Austria representative to the council of the European Society of General Practice/Family Medicine, Wonca-Europe' Executive Member of the Wonca Working Party on Education, Austria National representative to EURACT.
- II. **Prof. Dr. Alina Popescu**, MD, PhD - President of SRUMB (Romanian Ultrasound Society.)
- III. **Prof. Dana Stoian**, MD, PhD, Hab, CCD, FECSM, senior endocrine consultant, Department of Endocrinology, "Victor Babes" University of Medicine and Pharmacy, Timisoara, Romania
- IV. **Prof. Shlomo Vinker**, MD, MHA, WONCA Europe President, Executive Board member EGPRN
- V. **Dr. Peter Sigmund**, MD, Präsident der Steirischen Akademie für Allgemeinmedizin
- VI. **Dr. Carla Serra** - Member of the Board of the Ultrasound Course for SIUMB, Director of diagnostic and therapeutic ultrasound unit S. Orsola-Malpighi Hospital, Bologna, Italy
- VII. **Prof. Ioan Sporea**, MD, PhD, „Victor Babeş” University of Medicine and Pharmacy, WFUMB Center of Education, Regional Research Center, Academy of Medical Science, Timișoara, Romania
- VIII. **Dr. Gergely Ágoston**, MD, Vice president of the WG of the Hungarian Association of Cardiovascular Imaging, the HIT Ambassador of Hungary, Member of the Web and Communication Committee of the EACVI, Nucleus member of the ESC Editors Network, Associate Editor of Cardiologia Hungarica



CONFERENCE AGENDA

Day 1 / Friday, 9 SEPTEMBER 2022

07:45-08:00 - Registration of participants

I. Amphitheater: Hörsaal.

► 08:00-08:15 •Welcome speech - The 3rd Edition - Euroson POCUS School Vienna 2022.

Chairman: Dr. Mihai IACOB, EUVEKUS President

► 08:15-08:45 •The new concept of the clinical-ultrasound examination in current medical practice.

Keynote Speaker: Prof. Dr. Shlomo VINKER, WONCA Europe President

► 08:45-09:15 •Introduction to general ultrasonography based on sections and standardized plans for the daily practice of clinical ultrasound. The PoC- US applications in Family Medicine. Examination Technique and Sono-anatomy.

Speaker: Dr. Mihai IACOB, EUVEKUS President.

► 09:15-09:45 •Syndrome-focused ultrasonography.

Speaker: Dr. Mateusz KOSIAK, MD, Co-Founder EDUSON Poland.

► 09:45-10:00 Equipment on stage. Coffee break.

► 10:00-10:30 •Introduction to Ultrasound-based Elastography.

Speaker: Prof Dr Vito CANTISANI, MD., Ph.D., EFSUMB HONORARY TREASURER.

► 10:30-10:50 •The role of artificial intelligence in the complex evaluation of patients with liver steatosis.

Speaker: Prof. Dr. Adrian SAFTOIU, MD, Ph.D., MSc, AGAF, FASGE, EFSUMB Past President

► 10:50-11:20 •Multiparametric ultrasound in hepatology.

Speaker: Prof. Dr. Ioan SPOREA, MD, PhD, "Victor Babeş" University of Medicine and Pharmacy, WFUMB Center of Education, Regional Research Center, Academy of Medical Science, Timișoara, Romania

► 11:20-11:50 •Simple US - guided bedside interventions

Keynote Speaker: Prof Dr. Med. Christian JENSSEN, EFSUMB PRESIDENT.

► 11:50-12:00 Equipment on stage. Coffee break

► 12:00 -12:30 •FOCUS (Focused Cardiac Ultrasound) or Rapid Cardiac Assessment (RCA). Basic Cardiac Ultrasound for non-cardiologists.

Speaker: Dr. Gergely AGOSTON MD, Vice president of the WG of the Hungarian Association of Cardiovascular Imaging,

► 12:30-13:00 •Introduction to the Thyroid Clinical Ultrasound.

Speaker: Prof. Dana STOIAN, MD, PhD, Hab, CCD, FECSM, senior endocrine consultant, Department of Endocrinology, "Victor Babeş" University of Medicine and Pharmacy, Timișoara, Romania.

► 13:00-13:30 •Introduction to the breast ductal echography concept.

Speaker: Dr. Dominique AMY, MD, EFSUMB Breast US/Elastography Expert,

► 13:30-13:50 •Case recordings of the AI capabilities to diagnose cardiac problems in the primary healthcare

Zicherman Y., Binenbaum M., Evron I., Lyons M., Chadi B., Polliack G

Speaker: Yehuda ZICHERMAN D.Sc., Product Marketing, TRISO Technologies Ltd. Bet-Shemesh, Israel.

► 13:50-14:10

•Keynote speech on the topic: The scientific summary of the day.

Keynote Speaker: Prof. Dr. Shlomo VINKER, WONCA Europe President

► 14:10-14:40 - Lunch break

CONFERENCE AGENDA

II.Seminarraum B1 and B2

14.40 - 18.00 Workshop / Hands-on Session - All experts US practical demonstration:

Practical elements of POCUS applications to the abdominal, pelvis, chest, thyroid, and heart will be conducted together with our experts. Live transmission of ultrasonographic examinations (Live streaming broadcast).

► 14.40 -15.10

•WS.1.1 / Hands-on Session: Prof. Dr. Ioan SPOREA - Abdominal clinical ultrasonography.

► 15.10-15.40

•WS.1.2 / Hands-on Session: Video Breast US Demonstration by Dominique Amy.

► 15.40-16.10

•WS.1.3 / Hands-on Session: Dr. Mihai IACOB - Practical aspects of clinical ultrasonography (abdominal/pelvis/thyroid US).

► 16.10- 16.40

•WS.1.4 /Hands-on Session: Dr. Gergely AGOSTON - Basic Cardiac Ultrasound for non-cardiologists.

► 16.40 -17.10

•WS. 1.5/ Hands-on Session: Prof. Dr. Dana STOIAN - Thyroid clinical ultrasound - basic notion.

► 17.10 -17.40

•WS. 1.6/ Hands-on Session: Dr. Mateusz KOSIAK, - Thoracic ultrasonography.

► 17.40-18.00

•W.S. 1.7/ Final questions, answers, and discussions session.

Day 2 / Saturday, 10 SEPTEMBER 2022

► 07:45-08:15 - Registration of participants

I.Amphitheater: Hörsaal.

► 08:15-08:20 •Euroson POCUS School Briefing.

Chairman: Dr. MIHAI IACOB, EUVEKUS President

► 08:20-08:50 •Specification of Pocus in general medicine.

Speaker: Dr. Peter Sigmund, MD., Präsident der Steirischen Akademie für Allgemeinmedizin

► 08:50-09:20 •Current guideline projects of EFSUMB_Clinical Ultrasound - a dialogical examination.

Keynote Speaker: Christian Jensen, EFSUMB PRESIDENT.

► 09:20-09.50 •Results of the ThyroScreen Cross-Border Project. The risk stratifications of thyroid pathology. The use of artificial intelligence in thyroid ultrasound screening in primary healthcare.

Speaker: Dr. MIHAI IACOB, EUVEKUS President

► 09:50-10:10 **Equipment on stage. Coffee break**

► 10:10-10:40 •Sonography in emergency ambulance service

Speaker: Dr. Peter Sigmund, MD. Präsident der Steirischen Akademie für Allgemeinmedizin

► 10:40-11:10 •Breast ultrasound. Introduction to the ductal and conventional clinical ultrasound.

Speaker: Prof. Dana STOIAN, MD, PhD, Hab, CCD, FECSM, senior endocrine consultant, Department of Endocrinology, "Victor Babes" University of Medicine and Pharmacy, Timisoara, Romania

► 11:10-11:40 •Notions of Breast elastography.

Speaker: Dr. Dominique AMY, MD, EFSUMB Breast US/Elastography Expert, President de Ecole d'Echographie Sans Frontières.

► 11:40-12:10 •Indeterminate Focal Testicular Lesion: Role of Multiparametric Ultrasound Imaging.

Speaker: Prof. Dr. Paul S. SIDHU, BSc MBBS MRCP FRCP DTM&H FCIRSE FAIUM (Hon.)

► 12:10-12.30 **Equipment on stage. Coffee break.**

CONFERENCE AGENDA

I. Amphitheater: Hörsaal.

► 12.30-13.00 •Advances in liver imaging: B-mode to Multiparametric Ultrasound.

Speaker: Prof. Dr. Paul S. SIDHU, BSc MBBS MRCP FRCR DTM&H FCIRSE FAIUM (Hn.)

► 13.00-13.30 •Transabdominal ultrasound of the digestive tube.

Speaker: Prof. Dr. Ioan SPOREA, MD, PhD, "Victor Babeş" University of Medicine and Pharmacy, WFUMB Center of Education, Regional Research Center, Academy of Medical Science, Timișoara, Romania

► 13.30 - 13.50 •Thoracic ultrasonography.

Speaker: Dr. Mateusz KOSIAK, MD, Co-Founder EDUSON Poland.

► 13.50-14.00 •The scientific summary of the day.

Keynote Speaker: Prof. Shlomo VINKER MD, MHA, WONCA Europe President, Executive Board member of EGPRN.

► 14.00-14.30 - Lunch Break Symposium •Strain Elastography as a useful tool in daily practice

Video Presentation : Prof. Dr. Vito CANTISANI, MD, Ph.D., EFSUMB HONORARY TREASURER

II. Seminarraum B1 and B2 and Amphitheater Hörsaal.

14:30-15:30

ROUND TABLE: The future of using PoCUS in ambulatory healthcare from the perspective of professional organizations: WONCA EUROPE, EFSUMB, WFUMB, EUVEKUS.

Guest speakers: Prof. Dr. SHLOMO VINKER, WONCA Europe President / Prof Dr. Med. Christian Jenssen, EFSUMB PRESIDENT, /Dr. MIHAI IACOB, MD, EUVEKUS President / Professor Paul S. Sidhu, BSc MBBS MRCP FRCR DTM&H FCIRSE FAIUM (Hon.) WFUMB Treasurer, / Prof. Ioan Sporea, WFUMB COUNCIL MEMBER / Dr. Peter Sigmund, MD, Präsident der Steirischen Akademie für Allgemeinmedizin / Dr. Dominique Amy, MD, EFSUMB Breast US, Elastography Expert, President de Ecole d'Echographie Sans Frontières / Prof. Dr. Dana Stoian, / Dr. Mateusz Kosiak, Co-founder of EDUSON School Poland, / Dr. Gergely Agoston, Vicepresident of the Working Group of Hungarian Assoc. of Cardiovascular Imaging,

15:30 -17:45 Workshop / Hands-on Session - All experts US practical demonstration:

Practical elements of POCUS applications of the abdominal, pelvis, breast, thyroid, thoracic and heart will be conducted together with our experts. Live transmission of ultrasonographic examinations (Live streaming broadcast) to one post.

► 15.30-15.50 •WS.2.1/Hands-on Session: Prof. Dr. Christian JENSSEN - Abdominal clinical ultrasonography.

► 15.50-16.10 •WS.2.2/Hands-on Session: Prof. Dr. Ioan SPOREA - Practical aspects of clinical abdominal/pelvis US ► 16.10 -16.30 •WS.2.3 /Hands-on Session: Dr. Mihai IACOB - FOCUS Real-Time Demonstration / Smart Thyroid Software Demo.

► 16.30- 16.50 •WS.2.4 /Hands-on Session: Dr. Gergely AGOSTON - Basic Cardiac Ultrasound for non-cardiologists

► 16.50 -17.10 •WS.2.5/ Hands-on Session: Dr. Peter SIGMUND, Specification of Pocus in Family Medicine.

► 17.10 -17.30 •WS.2.6/ Hands-on Session: Prof. Dr. Dana STOIAN, Breast / Thyroid Ultrasound.

► 17.30-17.50 •WS.2.7/ Hands-on Session: Prof Paul Sidhu - POCUS - Tips and Tricks.

► 17:50-18:00

•Final evaluation of the participants - Awards - Certificates of Participation EFSUMB endorsed to all participants and EACCME credits.

► 19:00 - 23:00 - Gala Dinner



AWARD Certifications of Participations with
16 CME Credits by EACCME and
EFSUMB endorsement to all conference attendees



RAPID DETECTION OF NAFLD AND ITS EVOLUTIONARY STAGES TOWARD CIRRHOSIS IN THE TARGETED POPULATION THROUGH MULTIMODAL LIVER ULTRASONOGRAPHIC SCREENING (MLUS) AND ARTIFICIAL INTELLIGENCE WITH FIBROSIS RISK STRATIFICATION BY FAMILY PHYSICIANS.

Dr. Mihai IACOB, EUVEKUS President.

<https://doi.org/10.1016/j.ultrasmedbio.2022.04.138> Get rights and content

Background:

NAFLD is a global public health issue which progressively covers a spectrum of liver pathology as steatosis, steatohepatitis, fibrosis, and cirrhosis. This study aimed to evaluate the diagnostic accuracy of the multiparametric-liver-ultrasonographic screening with the uses of artificial intelligence performed by family doctors, compared to the evaluation performed by a specialist on patients with a high risk of NAFLD/NASH.

Methods: We conducted a multiparametric-liver-ultrasound screening(MLUS) on 4751patients, which presented as inclusion criteria: dyslipidemia, obesity, DM, metabolic syndrome (NCEP-criteria), cirrhosis, B / C viral hepatitis.

APRI-score and FIB-4 score were calculated for every patient to stratify the liver fibrosis risk. We use "standard protocol", which could improve reproducibility and facilitate dynamic comparison, in multimodal ultrasonography with standard liver scans. We established the cut-off /median-values (morphometric-US) of normal-ratios, between the anterior-posterior-diameters of the normal-liver-segments after Couinaud /lobes, with the kidney/spleen-long-axis (not influenced by fatty tissue loading).The high-risk patients with NAFLD/NASH were first examined by an experienced family doctor subsequently compared with ultrasound-review by the specialist, and agreement was evaluated using Cohen's-kappa-coefficient. We have developed a smart computerized diagnostic algorithm for NAFLD/NASH.



Results:

We identified 4751 patients with NAFLD/NASH/cirrhosis confirmed by a specialist.

The positive results of screening were: 2592-steatosis, NASH/steatofibrosis-971persons, and 22-cases with cirrhosis. The accuracy of Liver US Screening was: 95,87%, with 95%CI=95.27% to 96.42%, sensitivity: 97,12%, specificity: 91,59%, which were subsequently confirmed by the "Gold Standard" method through FibroScan.

The prevalence of liver pathology was: 77,48% with 95%CI: 76,26% to 78.66%. Reports of both groups of specialists for identifying NAFLD/NASH showed a **very-good-strength of agreement k=0.875**; 95% CI=0.864-0.887, standard-error: 0,005.

Conclusions:

The uses of multiparametric liver ultrasound screening (MLUS), morphometric-US (MUS), and artificial intelligence (AI), performed by trained family physicians are comparable to diagnostic liver ultrasonography performed by the gastroenterologist.

CLINICAL-ULTRASOUND-SCREENING OF CHRONIC KIDNEY DISEASE(CKD) IN HIGH-RISK PATIENTS WITH KNOWN CARDIO-RENAL-METABOLIC DISORDERS AND THE CORRELATIONS BETWEEN CLINICAL METHODS OF KDIGO ASSESSMENT OF RENAL FUNCTION AND RENAL MULTIMODAL ULTRASOUND BY FAMILY PHYSICIANS

Dr. Mihai IACOB, EUVEKUS President.

<https://doi.org/10.1016/j.ultrasmedbio.2022.04.137> Get rights and content



Background:

CKD is defined after KDIGO-guideline as abnormalities of kidney structure or function, present for more than three months, with implications for health and CKD is classified based on cause, eGFR category, and albuminuria category (CGA).

Diabetic Nephropathy (DN) is the leading cause of Chronic Kidney Disease (CKD), followed by high BP, and CVD being characterized in late stages by persistent or slight decreases of parenchyma and kidney sizes.

We aimed to analyze the correlations of both, renal tissue stiffness (Strain Elastography) and US morphometry, with clinical besides biochemical indicators in patients with CKD.

Method

We did an ultrasound screening on 1020 patients with DM, CVD, and BP. Patients were followed up with ultrasonography screening performed and also laboratory assays twice a year.

Renal-parenchyma thickness, length, kidney volume, kidney stiffness (elastography used/Strain-Ratio-SR), renal RI (Resistive Doppler Index) and estimated glomerular filtration rate (eGFR)/albumin to creatinine ratio (ACR-values), were analyzed using Pearson correlation and also ROC-curve-analysis to assess the kidney function.

We designed a diagnostic algorithm software. All patients were stored and counted into our electronic database.

Results

Our US screening, with an accuracy of 88%, found renal elasticity (Strain-Ratio-SR) worsened progressively from CKD-Stage 3 to 5 ($p < 0.001$).

The renal stiffness, measured by strain-elastography together with ultrasonographic kidney measurements, correlates very well with albuminuria (ACR) and rapid renal deterioration in patients with CKD. A statistically significant positive correlation was found between eGFR and both: Strain-Ratio ($r = 0.8013$, $p < 0.0001$) with parenchyma-thickness ($r = 0.7667$, $p < 0.0001$), and degree of kidney dysfunction.

The ROC statistical analysis of our US-methods confirmed a higher-level of diagnostic accuracy of Strain-Elastography, $p < 0.001$, AUC = 0.815, 95%CI: 0.790 to 0.838.

Conclusions

Our multimodal US screening suggests that both ultrasonographic parenchyma thickness measurements besides the renal stiffness (SR) measured by elastography, and renal RI (Resistive Doppler Index), could be some important imaging techniques for the follow-up care of CKD patients and could predict the rapid renal function deterioration in the ambulatory healthcare.

FEPO-THE FAST EXAMINATION METHOD FOR THE PARENCHYMAL ORGANS FOR EARLY DIAGNOSIS OF FOCAL LESIONS CORRELATED WITH A MULTIMODAL ULTRASOUND SCREENING AT THE PRIMARY HEALTHCARE LEVEL TO HIGH-RISK POPULATIONS.

Dr. Mihai IACOB, Andrei IACOB

Research Department in Family Medicine, EUVEKUS/EADUS/AEDUS - European Association for the Development of Clinical Ultrasonography in Ambulatory Health Care (Outpatient Health Care)., Wien, Austria

Background:

According to the current statistics of oncological pathology, we could now through relatively inexpensive methods such as multiparametric ultrasonography for increase diagnostic accuracy, both by using early positive and differential imaging diagnostics, as well as by developing programs and methods of general-targeted ultrasonographic screening, on high risk population, especially in developing countries/remote areas.

Over 80% of cancers could be diagnosed by ultrasonographic multimodal screening according to actual global cancer prevalence.

Our aim was the early diagnosis and quick treatment in the earliest stages of primary healthcare.

Method:

We report a multiparametric ultrasound screening (abdominal /pelvic /breast /thyroid / soft-tissues-ultrasonography or FEPO method) performed on a total of 5000 patients with positive oncological risk-factors, over 18 years, followed five-years, sex ratio=1:1.

We used a questionnaire to identify the presence of the risk factors as inclusion criteria. Patients, aged 18-50 years were made an ultrasound screening every two years and over 50 years annually by an ultrasound guideline (FEPO) and archived into an electronic database.

Positive patients had done the following ultrasound methods:

Gray-Scale /Doppler /Strain-Elastography/ CEUS/4D and „The Malignancy Ultrasound Score”(M.U.S) developed by us.

M.U.S., $p<0,001$.



Results:

We found a total of 310 patients with benign ($n=157$) and malignant tumors ($n=153$). The incidence of malignant tumors was: 3.06% at the high risk population. The sensitivity was 81%, specificity 90,94% with a high accuracy 90,54%, $p<0,01$, 5-year prevalence was: 6,2%, PPV=37,32%, NPV=98,68%. ROC analysis confirmed a higher level of diagnostic accuracy of multiparametric ultrasound (Gray-Scale, Doppler, Elastography US) compared with conventional Gray Scale Ultrasound, $AUC=0,996$, 95%CI= 0,981 to 1,00, $p<0.001$. To ANOVA comparative analysis the very significant statistical level had M.U.S., $p<0,001$.

Conclusions:

FEPO-methodology correlated multiparametric ultrasound targeted screening proves to be a very effective method with high accuracy 90% for the early detection of hypervascular tumors in the asymptomatic stage, which can confirm malignancy and the need for biopsy and histological outcome as "the Gold Standard method"

References:

- 1.National Cancer Institute (NCI). Common cancer types. NCI website. <https://www.cancer.gov/types/common-cancers>. 2018. Accessed August 10, 2018.
- 2.American Cancer Society (ACS). Cancer facts & figures 2018. ACS website. <https://www.cancer.org/research/cancer-facts-statistics/all-cancer-facts-figures/cancer-facts-figures-2018.html>. 2018. Accessed April 9, 2018.
- 3.Henrikson NB, Bowles EJA, Blasi PR, et al. Screening for Pancreatic Cancer: A Systematic Evidence Review for the U.S. Preventive Services Task Force. Rockville, MD: Agency for Healthcare Research and Quality; 2019.
- 4.United Nations Development Programme (UNDP). Human Development Index: 2016 Rankings. UNDP website. <http://hdr.undp.org/en/2016-report>. Published 2016. Accessed December 1, 2017.
- 4.Hartink F, Konings KJ, Klug J, et al. Dutch Research Group on Pancreatic Cancer Surveillance in High-Risk Individuals. A multicentre comparative prospective blinded analysis of EUS and MRI for screening of pancreatic cancer in high-risk individuals. *Gut*. 2016;65(9):1505-1513. doi:10.1136/gut-2014-308009PubMedGoogle ScholarCrossref
- 5.Barnes CA, Kryzwyda E, Lahiff S, et al. Development of a high risk pancreatic screening clinic using 3.0 T MRI. *Fam Cancer*. 2018;17(1):101-111. doi:10.1007/s10689-017-0057-xPubMedGoogle ScholarCrossref
- 6.Gangi A, Malafa M, Klapman J. Endoscopic ultrasound-based pancreatic cancer screening of high-risk individuals: a prospective observational trial. *Pancreas*. 2018;47(5):586-591.PubMedGoogle Scholar
- 7.Canto MI, Almaro JA, Schulick RD, et al. Risk of neoplastic progression in individuals at high risk for pancreatic cancer undergoing long-term surveillance. *Gastroenterology*. 2018;155(3):740-751. doi:10.1053/j.gastro.2018.05.035PubMedGoogle ScholarCrossref
- 8.Fukuda A, Wang SC, Morris JP, et al. Sta3 and MMP7 contribute to pancreatic ductal adenocarcinoma initiation and progression. *Cancer Cell*. 2011;19(4):441-55. (PMAC free article) [PubMed] [Google Scholar]

RESULTS OF THE THYROSCREEN CROSS-BORDER PROJECT. THE RISK STRATIFICATIONS OF THYROID PATHOLOGY. THE USE OF ARTIFICIAL INTELLIGENCE IN THYROID ULTRASOUND SCREENING IN PRIMARY HEALTHCARE.

Dr. Mihai Iacob, Andrei Iacob

Research Department in Family Medicine, EUVEKUS/EADUS/AEDUS - European Association for the Development of Clinical Ultrasonography
Ambulatory Health Care (Outpatient Health Care), Wien, Austria



Keywords: thyroid malignancy, artificial intelligence, smart thyroid ultrasound software, ultrasound screening, diffuse or focal thyroid pathology.

Background:

This project has three stages. The first step was the development of a smart computerized diagnostic algorithm used to stratify the risk in thyroid pathology, Ultrasound based. It set the optimum time to achieve a thyroid biopsy (FNAB). We have used the latest international classifications (two international scores: EU-TIRADS/ACR-TIRADS), besides a scoring made by us, correlated with the pathological results. The second stage included a Targeted Thyroid Screening in a population with high risk, statistically significant. Finally, we are launching a cross border interdisciplinary-multicenter-US-Screening.

Research questions:

How can we early diagnose thyroid malignancies in the high risk population in primary healthcare by using new medical technology and artificial intelligence?

Method:

We report a targeted thyroid screening performed on 4386 apparently healthy adults with oncological risk factors+, aged over 20 years, followed for five years. We used the TIRADS classification by Russ modified and Strain Elastography, with both the elastographic scores by Rago and semiquantitative Strain Ratio(SR), for standardization and to establish if fine needle aspiration biopsy(FNAB) should be performed. The positive patients with focal thyroid lesions found at this screening by family doctors were validated by endocrinologists through ultrasonography, FNAC, and histopathological or cytological examination.

We designed an Ultrasound Scoring System (USS) for predicting malignancy and diagnostic algorithm software.

All patients were stored and counted into a Smart Thyroid Ultrasound Software. Finally, we compared ultrasound scores designed by us, with the histological results as "Gold Standard" method.

Results:

In this study, they were found: 861 patients with thyroid diffuse disease and 696 with different focal lesions. Prevalence of thyroid pathology was: 38.99%, 95%CI: 37.54% to 40.45% with screening sensitivity: 96.49%-specificity: 96.52% and a high accuracy of 96.51%, PPV: 94.66%, NPV: 97.73%, statistically significant, $p < 0.01$. The ROC analysis of our US methods confirmed a higher level of diagnostic accuracy of Strain-Elastography, $p < 0.001$, $AUC = 0.995$, 95%CI: 0.97 to 1 correlated finally with the pathological result. Our cut-off-value of SR was: 2.5.

Conclusions: Performing Doppler Triplex Ultrasound Screening together with Strain-Elastography, had the best accuracy for the analysis of the vascular network and the tumor stiffness, for differentiating "benign versus malignant" of the thyroid tumors and for diagnosis of the diffuse thyroid diseases by family physicians with uses of the artificial intelligence as a support tool for the risk stratification.

Points for discussion:

How can we improve the early diagnosis of thyroid malignancies in the context of increasing their prevalence in industrialized countries?

Is it possible to perform thyroid ultrasound in a multidisciplinary screening team by family doctors specially trained in this regard?

How can artificial intelligence help us with ultrasonography technology as a diagnostic method in the practice of family doctors?

CURRENT GUIDELINE PROJECTS OF EFSUMB AND THE ROLE OF POCUS

Prof. Dr. med. Christian Jenssen
Brandenburg Institute for Clinical Ultrasound at Medical University Brandenburg
"Theodor Fontane", Neuruppin, Germany
Krankenhaus Märkisch-Oderland, Department of Internal Medicine, Strausberg/
Wriezen, Germany, EFSUMB President 2021 - 2023, c.jenssen@kholm.de



The year 2022 marks the 50th anniversary of the European Federation of Societies for Ultrasound in Medicine and Biology (EFSUMB). Since 2004, EFSUMB Guidelines and Clinical Practice Recommendations have become a trademark over the last two decades. Starting with CEUS in 2004, the thematic spectrum was expanded, in 2012 to elastography, in 2015 to interventional ultrasound, in 2017 to gastrointestinal ultrasound, and in 2021 to musculoskeletal ultrasound. The first update of the CEUS Guidelines of 2008, the Elastography Guidelines of 2012, and the non-hepatic CEUS Guidelines of 2012 became real bestsellers with more than 1000 citations each.

Publication of the final Part 7 of the Gastrointestinal Guideline on Ultrasound in Functional Disorders of the Gastrointestinal Tract last year marks the successful completion of one of EFSUMB's largest Guideline projects, initiated by our former President Odd Helge Gilja [Maconi G et al. *Ultrasound Int Open*. 2021 Apr;7(1): E14-E24]. Under the leadership of Dana Fodor, EFSUMB has added another important area to its guideline map, musculoskeletal ultrasound, with two guidelines published in *Ultraschall/EJU* in 2021 and 2022 [Fodor D et al. *Ultraschall Med*. 2022 Feb;43(1):34-57; Naredo E. et al. *Ultraschall Med*. 2021 Nov 3, Online ahead of print].

The long-awaited PoCUS guidelines were held up with the lead author Bob Jarman getting COVID. Its 1st part (Common, Heart, and Pulmonary applications) was submitted at the end of 2021 to *Ultraschall/EJU*, is still under review, and will be published hopefully in one of the next issues. EFSUMB decided to address the complex issue of multiparametric ultrasound with guidelines on three small organs - thyroid, breast, and testis - as well as the pancreas and liver. The Education (EPSC) and Publication Committees embarked on a "Professional Standards in Ultrasound Position Paper", led by Matthias Wuestner and Maija Radzina, which has been published by *Ultraschall/EJU* online recently. The important work to strengthen the professionalism of ultrasound in Europe will continue this year.

Continuously, we work on three goals:
1) To establish the guidelines as a basis for clinical application, to achieve worldwide acceptance and a broad impact;

this includes closer cooperation with several medical-scientific societies which are interested in special fields of ultrasound. We have recognized the need to expand the reach of our guidelines beyond the circle of ultrasound professional societies. Partnership projects such as the inclusion of two important EFSUMB guidelines in the United European Gastroenterology Guideline App, which currently contains 19 guidelines and has been downloaded by 19,000 users, serve this purpose. A major effort in the next years will be to also develop an own Ultrasound Guideline App, most likely together with WFUMB and the other continental ultrasound federations. Just in the last weeks we together with the European Society of Emergency Medicine (EuSEM) have developed a joint position paper on "Emergency Medicine PoCUS Stewardship". We are looking forward to intensifying the close contact with EUVEKUS to decide on joint projects in the field of PoCUS in general and family medicine.

2) to further develop the methodological quality of the guidelines. We have rightly been criticized that our guidelines no longer meeting the highest contemporary methodological standards. We have addressed this criticism and adopted a guideline development strategy and strict methodological principles for future guidelines at the EUROSON congress in Poznan in 2018 [Jenssen C et al. *Ultrasound Int Open*. 2019 Jan;5(1):E2-E10]. These principles will be implemented for the first time in the POCUS and MPUS Guidelines to a large extent, including the use of the PRISMA 2020 reporting system for systematic literature assessment

3) to reflect the diversity of clinical ultrasound applications also in our guidelines. The topics of our major guideline projects make it clear that we have been very focused on multiparametric high-end ultrasound. However, we have recognized that those who practice clinical ultrasound as GPs, FPs, and in other outpatient settings also need support and direction. We are pleased to see the widespread adoption of ultrasound ("democratization"), but we also recognize the risk when ultrasound is increasingly performed by inadequately trained practitioners. Therefore, we will continue to focus heavily on including those topics in guidelines and position papers that are relevant to the vast majority of ultrasound practitioners.

SIMPLE US-GUIDED BEDSIDE INTERVENTIONS

Prof. Dr. med. Christian Jenssen
Brandenburg Institute for Clinical Ultrasound at Medical University Brandenburg
"Theodor Fontane", Neuruppin, Germany
Krankenhaus Märkisch-Oderland, Department of Internal Medicine, Strausberg/
Wriezen, Germany, EFSUMB President 2021 - 2023, c.jenssen@kholm.de



In 1976, the German internist and gastroenterologist Gerhard Rettenmaier founded his concept of "*continuation of clinical examination using ultrasound*", which was later also referred to as "*clinical ultrasound*" and, in its focus on a concrete clinical situation directly at the patient's bedside or in the practice, as "*point-of-care ultrasound (PoCUS)*". What is fascinating about this concept is that ultrasound (US) is directly involved in the doctor-patient interaction. It has the potential to bring together factual objectification with interpersonal encounters. Where normally technical means of diagnosis create distance between the general practitioner (GP) or family physician (FP) and his patient, leading to roundabouts and occasionally dead ends, the small US device in the hand of the physician becomes a technical bridge, promotes communication, creates closeness and becomes a "*seventh sense*" of the physician. It is a technique close to the human being, which ideally embeds the often distanced ("*tube situation*" of large-scale device imaging) technical diagnostics into an interpersonal encounter situation with a bi-directional, dynamic information transfer. So the clinical US, especially PoCUS, in the hands of the GP and FP becomes a "*dialogic diagnostic modality*" (G. Maio, 2014).

But this concept applies not only to the diagnostic US. Several simple therapeutic interventions can be performed and their outcome monitored within the PoCUS concept - for example, by FPs, GPs, or palliative care physicians (PCPs) not only in the doctor's office but also during home visits of their patients. PoCUS significantly enhances the GPs and FP's ability to take rapid and immediate therapeutic action independent of diagnostic providers who are relatively distant from the patient. Last but not least, this also strengthens the patient's trust in the doctor, who "lends a hand" very directly and thus alleviates symptoms and suffering.

This development has been made possible by the advent of battery-powered, inexpensive pocket-sized scanners (handheld ultrasound systems, HH-US). HH-US systems are clearly on the rise. While the projected growth rates for premium cart US systems for 2022 - 2025 are 2.9 - 3.7% per year, the market for HH-US systems is expected to grow 18.9 - 32.9% over the same period. HH-US equipment is also becoming more affordable. The cost of many systems is between 2500 and 4500 Euros. Therefore, it is hard to imagine that in 5 years a general practitioner or family physician will not have such a device in his or her medical kit and use it as naturally as his or her stethoscope - or perhaps in place of it. Moreover, even specialized non-physician health care providers (e.g., palliative and family nurse practitioners) can, with brief and focused training, be enabled to make simple yes-or-no diagnoses with portable US devices (ascites or pleural effusion; incomplete bladder emptying) and even to perform simple interventions with such devices. The US thus no longer remains a specialist method but can be used by the GP, FP, and PCP, the specialized palliative care nurse, the midwife, and the community nurse. "Seeing is believing", and therefore US guidance can facilitate the performance of several basic interventions. In this lecture, some simple PoCUS-guided bedside interventions will be presented and briefly discussed.

PoCUS-guided insertion of nasogastric tubes

Nasogastric tube insertion by FPs, GPs, and PCPs may be necessary for patients with gastric fluid accumulation, chronic ileus, or to temporarily provide nasogastric nutrition. Nasogastric tube insertion is usually a simple technique that does not require imaging support in most patients. However, failure and misplacement (e.g., tracheobronchial) can occur and in rare cases can result in severe complications, for example, hypopharyngeal perforation, esophageal perforation, aspiration of fluids, hemorrhage, and pneumothorax. Recent studies have shown that US guidance can improve the first-attempt and general success rates from 90% to nearly 100%, reduce procedure time, and prevent misplacement of the probe.

PoCUS-guided urinary bladder catheterization

Bladder catheterization is one of the most performed simple medical procedures. PoCUS allows rapid assessment of bladder volume and residual urine, facilitating the indication for bladder catheterization. At the same time, PoCUS can be used in cases of insufficient bladder drainage to diagnose and correct catheter malpositions. When bladder catheter positioning is difficult, PoCUS can be used to track and facilitate bladder catheter insertion. Suprapubic bladder puncture should generally be performed only under ultrasound guidance. Very rarely, do problems occur during the removal of bladder catheters, usually due to adhesion of the balloon channel in the catheter. If the catheter cannot be removed even after cutting, the balloon can be punctured and deflated with a thin cannula under US guidance.

PoCUS-guided peripheral venous access

In patients with poor venous conditions, blood sampling and insertion of an indwelling peripheral venous cannula can be time-consuming and enervating procedures that can cause both pain and psychological distress for the patient. In the vast majority of cases, hand-held ultrasound devices succeed in detecting a suitable vein sonographically. This vein can then be punctured sonographically assisted or, better, under direct ultrasound vision with an appropriate needle or indwelling vein cannula. The procedure is recommended in guidelines because numerous studies have demonstrated its high effectiveness and safety. Complications of venous access such as thrombosis and infection as well as hypo- or hyperhydration can be detected well with handheld US devices. Nurses and other non-physician care providers can achieve competence in US-guided venous access skills with relatively little training.

PoCUS-guided paracentesis and thoracocentesis

The diagnosis of fluid accumulation in body cavities is one of the simplest tasks of ultrasonography and substantially reduces false diagnoses of ascites and pleural effusions on clinical examination. The cause of abdominal distension or shortness of breath can be clarified very quickly. US-guided puncture or drainage of pleural effusions, ascites, and pericardial effusions can significantly reduce risks and reliably avoid misplacements. PoCUS-guidance is useful to avoid accidental puncture of intraabdominal organs and vascular structures, to optimize the fluid pocket for the needle, and to avoid areas with a thick abdominal wall or vessels. Guidelines, therefore, recommend that paracentesis, thoracocentesis, and pericardiocentesis should only be performed under US assistance or guidance. Since these procedures are very safe even in patients with coagulation disorders, anti-coagulants, or anti-platelets, there is no reason why they should not be performed on an outpatient or bedside basis, even in the home-care setting.

THE NEW CONCEPT OF THE CLINICAL-ULTRASOUND EXAMINATION IN CURRENT MEDICAL PRACTICE

Prof Shlomo Vinker, WONCA Europe President, Israel

3rd EUROSON PoC-US SCHOOL 2022 Conference, Vienna, 9-10th September 2022



I ended my lecture last year saying “POCUS represents the family medicine of the future”. This year I will try to share with you the progress that was made since then. The introduction of POCUS starts now in medical school. In a survey among medical schools in the US (1) it was found that 57% schools had an approved POCUS curriculum, with 8% offering a longitudinal 4-year curriculum. Barriers to implementing POCUS training included lack of trained faculty, lack of time in current curricula, and lack of equipment. It means that the next generation of trainees will have the basic knowledge and skills to integrate POCUS to the residency program. In the US 81% of departments of family medicine have at least 1 POCUS-trained faculty, with 44% of departments using POCUS in some ambulatory clinical care. The purchasing of equipment and billing for POCUS were described by FMCs as difficult (2). POCUS had been introduced to the residency program in Zambia and in a survey it was found that POCUS changed management in 65.8% (235/357) of patient encounters, most commonly leading to a medication change (3).

It is an example of introducing the technology to LMIC, but the same may be relevant in other countries. It is important to note in parallel to introducing POCUS to undergraduate and residency programs, we should also plan a “catchup programs for working family physicians.

In a qualitative study from Sweden, family physicians shared their experience in acquiring basic POCUS competences (4). They started with formalized training sessions at hospital departments or courses.

Later they developed and expanded their skills through additional courses and continuous self-study practice on patients often while consulting internet sources, textbooks or colleagues. Time constraints and financial aspects were mentioned as barriers to their ultrasound training.

In conclusion, it is time for wide implementation of POCUS in primary care and family medicine. The plan should be multidimensional focusing on training in all levels and along the entire professional career.

1) Russell FM et al. The State of Point-of-Care Ultrasound Training in Undergraduate Medical Education: Findings From a National Survey. *Acad Med* . 2022 May 1;97(5):723-727.

2) Capizzano JN et al. Current State of Point-of-Care Ultrasound Use Within Family Medicine. *J Am Board Fam Med* 2022 Jul-Aug;35(4):809-813.

3) Haldeman MS et al. Resident perception on the impact of point-of-care ultrasound in clinical care at a family medicine training program in Zambia. *Ultrasound J* . 2022 May 15;14(1):18.

4) Andersen CA et al. Learning strategies of general practitioners striving to achieve point-of-care ultrasound competence: a qualitative study. *Scand J Prim Health Care*. 2022 Mar;40(1):67-77.

5) Andersen CA et al. General Practitioners' Perspectives on Appropriate Use of Ultrasonography in Primary Care in Denmark: A Multistage Mixed Methods Study. *Ann Fam Med*. 2022 May-Jun;20(3):211-219.

INDETERMINATE TESTICULAR LESIONS: ROLE OF MULTIPARAMETRIC ULTRASOUND

Prof. Dr. Paul S. SIDHU

An incidental Intra testicular lesion is an uncommon finding on a routine ultrasound examination of the scrotum but can present as a conundrum in the management of the patient. The surgical practice has been to offer all men with a palpable intra-testicular lesion an orchidectomy on the understanding of the surgical literature that over 90% of these lesions are malignant. With the advent of the practice of ultrasound for many different scrotal symptoms, many lesions that are not palpable are discovered. Many studies indicate that these small lesions are likely benign, most often an area of Leydig cell hyperplasia. In a group of infertile men with focal testicular lesions that were found incidentally on ultrasound, 88% were benign. Ultrasound is the main imaging modality for the scrotal sac, with high resolution and excellent detection of even very small lesions. Generally, B-mode and color Doppler ultrasound are the main techniques used. The premise is that if there is color Doppler flow within a lesion, it is likely to be malignant. However, with the advent of new techniques of contrast-enhanced ultrasound and tissue elastography, added information can be gained with the outcome the avoidance of an orchidectomy for a benign abnormality. The term multiparametric ultrasound imaging is used to describe this ability, and the techniques will be applied in the lecture to demonstrate how this may improve the confidence in dividing the incidental lesion into a benign or malignant entity.

Recommendations

1.It is common to find an incidental intra-testicular lesion.

2.Nearly all (88%) incidental intra-testicular lesions, that are non-palpable are benign.

3.Orchidectomy can be avoided using all US tools - multiparametric US.

4.The highest incidence occurs in the infertility clinic with male factors.

ADVANCES IN LIVER IMAGING: B-MODE TO MULTIPARAMETRIC ULTRASOUND

Prof. Dr. Paul S. SIDHU

BSc MBBS MRCP FRCR
DTM&H FCIRSE FAIUM
(Hon.) Past President of
EFSUMB Professor of
Imaging Sciences Acting
Corporate Medical Director
(Operations) Department of
Radiology King's College
Hospital London. United
Kingdom



Conventional ultrasound imaging of the liver has used B-mode for several years. This gives an excellent assessment of the liver, assessing parenchymal changes, liver size, smoothness of the outline, and the presence of focal liver lesions.

This provides a highly informative investigation and documentation of liver disease. The introduction of Doppler techniques, spectral, color, and highly sensitive methods has further improved the diagnostic capabilities of an ultrasound examination of the liver. The newer techniques of contrast-enhanced ultrasound, elastography, and fat quantification methods have further expanded the usefulness of the liver ultrasound examination. All these different ultrasound techniques come under the umbrella term 'Multiparametric Ultrasound', and allow for a 'one-stop' clinic for the assessment of liver disease.

THE USE OF MAMMARY ECHOGRAPHY IN THE DETECTION OF BREAST CANCER UNDER ONE CENTIMETRE IN SIZE

Dr. med. Dominique AMY

Vice-president of the European Society of Breast Echography,
IBUS board member (international breast ultrasound school),
CFFE director. (centre francophone formation en Echographie,
President of : Ecole d' echographie sans frontiere



Dr. Dominique AMY has been involved for more than 30 years in the research and teaching of the development of breast ultrasound.

The lobar approach to breast echography focuses on the lobar anatomy in association with the « sick lobe concept » (following the « sick lobe theory » of Pr T.TOT 2005). Initially, Dr. M.TEBOUL was the first to describe the « Ductal Echography for the breast (1995 and 2004)

The new ultrasonic technique is capable to depict the anatomic breast structures and the early development of cancer, leading to a revolutionary surgical approach suitable for the treatment of multifocal and multicentric breast cancer.

A large number of doctors including radiologists, oncologists, surgeons, pathologists as well as residents should be concerned by this new concept.

Introduction

Three fundamental questions have to be asked before embarking on a breast investigation using the various techniques of medical imagery:

- How does breast cancer appear and where does it take shape in the breast?

- Why has mammography which is the 'gold standard in diagnosis to be complemented by other forms of investigation?

- What is the difference between conventional echography and ducto-radial echography?

1.1 The study of the research work carried out by Professor T. Tot and Dr. Nakama will enable us to answer the first question, namely the understanding of the origin of breast cancer and the modes of its development.

1.2 Although mammography is an essential tool for investigation, it has some serious shortcomings, with a high rate of false positives and a significant rate of false negatives. These drawbacks are because the X-rays allow an investigation of the conjunctival and fatty structures, but do not visualize the epithelial (lobular and ductal) elements. As a consequence, in the case of cancer, only the stroma reaction and the architectural distortions are visible on the mammograms whilst the tumor itself is X-ray-transparent.

On the other hand, mammography reveals the micro-calcifications which can be related to some cancers, and, from that point of view, it remains quintessential for the detection of breast cancer.

1.3 Conventional echography is a technique derived from the radiological exploration of the breast. Orthogonal scanning of the breast is carried out in a systematic, repetitive way, to detect a tumor, be it benign or malignant. Unfortunately, like mammography, this type of echography does not take breast anatomy into account. The examiner looks for a lesion located in a fibro-glandular unit, in the 'corpus mammae' in the quadrants, etc...

Without referring in any way to the anatomic structures such as the lobes, the lobules, the ducts, not to mention the TDLUs: these words never appear in the accounts of ultrasound investigations of the breast. This is why the technique of ductal echography (initiated by Dr. Teboul, a radiologist in Paris) is going to be described at length here to amend the shortcomings of conventional echography.

1.4 A fourth question is to be added, concerning the role of MRI in the detection of breast cancer. It is a technique that is perfectly well-adapted to the exploration of mammary structures, but its purposes are well-targeted and it cannot be used for the general screening of the population. It is an invasive, expensive, and restricted examination because of the limited number of available units in hospitals or centers of diagnosis.

MRI also has a major drawback; it overlooks the anatomic investigation of the breast, because of the systematic orthogonal slices carried out right and left.

1.5 To conclude this introduction, it is essential to say that the investigation of a breast in search of cancers below one centimeter in size is a difficult process that must combine mammography and echography (preferably ductal), that, in certain cases, MRI has to be used, and that interventional methods are often needed (such as fine needle puncture, mamotome, laying off a harpoon) In some cases, ductal echography will be the only technique used (very young women with radiologically dense breasts, pregnancy...)

Cancer diagnosis at an early stage requires absolutely all sources of information such as radiology, echography, MRI, and anatomic pathology, to be as accurate as possible.

Conclusion

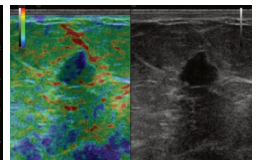
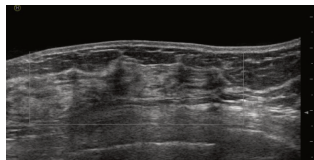
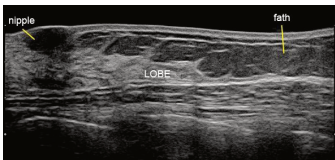
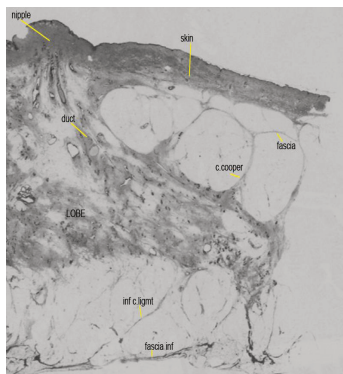
Ductal echography must become the key technique for the diagnosis of breast cancer: it is irreplaceable and corresponds to a major improvement in the investigation of mammary pathology. The significant improvements linked to the introduction of digital echography have allowed us to understand breast anatomy, and its morphological as well as physiological variations. Thanks to the first editions of the works of GALLAGHER, TEBOUL, NAKAMA, TOT, UENO, and DOLFIN, we are now able to understand better the origin, the nature, and the mode of development of breast cancers. Prof. Tot's 'Sick Lobe Theory' really is a revolution in the approach to cancer which is no longer a tumor but a real disease that has to be treated as such. The diagnosis of millimeter breast cancers remains difficult. It requires specialized training, making use of all the information collected through mammograms and conventional echography (we do not deny the contribution of these techniques, despite their lack of precision), and even MRI. Well handled, ductal echography allows an improvement in the diagnoses of multifocal and/or diffuse cancers below one centimeter in size.

The particular case of diffuse lobular cancers (not visible in mammography, badly visible in echography, nonspecific in elastography) remains a nightmare for the radiologist.

Because of this, specific training is required, and also the use of a good echograph. The point is no longer to look for a lesion in a breast but to analyze the ductal and lobular structures located in the various lobes. It will then be possible to identify the non-radio-visible benign lesions (epithelial proliferation, lobular and ductal micro-cysts, ectasia, papilloma, and papillomatosis) and distinguish them from small intra-ductal or intra-lobular, multifocal or multicentric malignant lesions which until then were overlooked. The perfect correspondence between the echographic and histologic observations is the best proof of the efficiency of ductal echography.

The confirmation of the echographic discoveries by Prof. Tot is highly gratifying and urges us to develop the technique of ductal echography more and more and to train younger generations to practice it, all the more so as the new equipment (digital machines, new generation specific probes, Doppler, elastography, 3D, etc...) allow us to improve the diagnostic performances considerably. The impressive number of new cases of breast cancers (one in eight women), and their long-overlooked multifocal or multicentric character, is a challenge that we must hasten to take up.

Dr. Dominique AMY
EFSUMB Breast
Ultrasonography



Lobar localization inside the breast.

A perfect correlation between the histologic section and the echographic lobar scanning.

MULTIPARAMETRIC ULTRASOUND IN HEPATOLOGY



Prof. Dr. Ioan SPOREA

„Victor Babeş” University of Medicine and Pharmacy, WFUMB Center of Education, Regional Center of Research in Advanced Hepatology, Academy of Medical Science, Timișoara, Romania

Non-alcoholic Fatty liver disease (NAFLD) became at this moment the main hepatological disease in the developed world. Decreasing the chronic viral hepatitis number (HBV and HCV), controlled or cured with oral treatment, hepatological diseases in connection with metabolic conditions, become the main field of activity for the hepatologist. Obesity affects 25-30 % of the population in developed countries, type 2 diabetes mellitus (type 2DM) affects 1/11 of the adult population, and metabolic syndrome is very frequent. All these 3 generating conditions, affect quite often the liver, mainly without any symptoms, and finally can drive to severe fibrosis or cirrhosis, with well-known complications (portal hypertension, decompensation, hepatocellular carcinoma). But which is the role of a physician in this entity: NAFLD? First to know about this disease, to know about the evolution of this, to know the generating causes, and finally, to have the diagnosis, as soon as possible. Taking the model of MRI, which is considered to be a Multiparametric method, in the last years, ultrasound (having multiple developments the last time), became too a Multiparametric method (Multiparametric Ultrasound or MPUS). This MPUS capacity is used for the diagnosis of focal liver lesions (FLL) or diffuse liver disease. For the detection of FLL, standard ultrasound is a sensitive method, but with low specificity. Using immediately a Contrast Enhanced Ultrasound (CEUS), using SonoVue, the differentiation between benign and malign hepatic lesions can be 90% (was shown in many meta-analyses and large published papers), and for a specific lesion can be approx. 80-85%. A combination of CEUS with liver elastography can improve the accuracy of diagnosis, especially for the diagnosis of hepatocarcinoma. For diffuse liver disease, ultrasound is useful for the detection and quantification of liver fatty infiltration, for stiffness evaluation using shear wave ultrasound-based elastography, and more recently for viscoelastic property (like a surrogate of inflammation). For the diagnosis of liver steatosis, liver ultrasound is a simple and util method, with a sensitivity and specificity for moderate and severe steatosis (clinically significant) of more than 80%. Quantitative assessment of liver steatosis can be performed with FibroScan, with CAP module (Controlled Attenuation Parameter), with an accuracy of 80-90%. The evaluation is made in only a few minutes, painless and repetitive. More recently, modern ultrasound machines have modules for steatosis quantification (QUS) (Canon, General Electric, Hitachi, Aixplorer, Samsung, Siemens), which identify and quantify the presence of steatosis, looking at posterior attenuation or backscattering of ultrasound beam. But for the patients with NAFLD, the prognosis is given by the severity of the fibrosis. For this reason, the practitioner must quantify the severity of the fibrosis, in the patients with metabolic risk. This evaluation can be performed using simple biological tests, like FIB 4 (using the age of the patient, ALT, AST, and thrombocytes) or NAFLD score (using the age of the patient, BMI, presence of diabetes mellitus, AST/ALT ratio, thrombocytes and serum albumin) or others scores (and this can be performed maybe to the basic level: GP), or can use ultrasound-based elastography systems. Fibroscan is the oldest and most well-known elastographic system (with a diagnostic accuracy of 80-95% and that increase with the severity of fibrosis). In the last 10-15 years elastography was introduced in the vast majority of performant ultrasound systems, like pSWE or 2D-SWE (point or bi-dimensional). The diagnostic accuracy of these systems is similar to FibroScan. Evaluation of the viscoelastic property of tissue is of great importance in clinical practice, this can be equivalent to inflammation. Looking at inflammation with ultrasound, this is a hope to make a differentiation between simple steatosis and steatohepatitis, without using liver biopsy. But which are the novelties in this field? Introduction of modules for fatty liver quantification in ultrasound machines of medium class (General Electric P system) or quantification of fibrosis with the same type of medium class machines (Philips, General Electric). What means this? That this type of ultrasound machine can be used as a „point of care” method in the consultation room. In this modality, the patients with metabolic risk and where ultrasound examination found significant liver steatosis, this can be quantified (and followed in time) and using elastography, the fibrosis can be assessed. Then in a few minutes and without any displacement of the patient, steatosis, and fibrosis can be quantified. Having all these aspects in an ultrasound machine, we can say that ultrasound became an MPUS for the evaluation of hepatological pathology, don't matter whether is an FLL or diffuse liver disease. Then having a good and simple machine, in many situations like a “point of care” method, we can start to screen the population at risk. Probably that this strategy must be adopted as soon as possible, because some studies have shown that type 2 diabetes patients have in 80-90% of cases significant steatosis, and significant fibrosis appears in 20% of the diabetic and metabolic patients. Modern ultrasound systems make it easy and simple a screening hepatological conditions and can be used for real liver screening in patients at risk.

TRANSABDOMINAL ULTRASOUND OF DIGESTIVE TUBE (GIUS)

Prof. Dr. Ioan SPOREA

„Victor Babeș” University of Medicine and Pharmacy, WFUMB
Center of Education, Regional Center of Research in Advanced
Hepatology, Academy of Medical Science, Timișoara, Romania



The medical evaluation of the digestive tract by ultrasound is relatively recent. For a long time considered to be an impediment in the investigation of abdominal organs, because of air, ultrasound has recently been used more and more often. The results of the ultrasound examination allow for establishing difficult diagnoses. The ultrasound evaluation of the digestive tract represents a “refinement”, as it is addressed to experienced ultrasonographers, usual specialists in this imaging domain. The ultrasonography of the digestive tract requires not only a trained specialist but also quality equipment. Besides the classical convex multifrequency transducer (3.5 MHz usually), it is also useful to examine with a linear multifrequency transducer (5-10 MHz) (depending on the digestive segment examined). The time dedicated to the examination of the digestive tract should be sufficiently long for detecting changes in different segments and also notice possible complications of organ disease. In the normal condition of transabdominal examination of the digestive tube, in most cases, ultrasound will normally visualize the **gastroesophageal junction**. The examination is performed at the epigastric level, in the sagittal section, while the left hepatic lobe is used as an ultrasound window (a small left lobe might render the examination of the gastroesophageal junction impossible). The **cancer of the gastroesophageal junction** appears as a hypoechoic mass varying in size, located in the junction area. The tumor contains air, like any digestive structure, and swallowing water will allow us to obtain additional ultrasound information. **The stomach:** from the point of view of medical sonography, the stomach represents the segment of the digestive tract that is most facile to examine by using transabdominal ultrasound. The high incidence of gastric diseases (neoplasms, lymphoma, gastric emptying disturbances, etc.) makes gastric transcutaneous ultrasound an interesting side of this area in medicine. The stomach may be examined in fasting conditions, through epigastric transverse or sagittal sections. In case of incomplete or difficult visualization, 500-700 ml of still water will be orally administered to the patient. **Gastric cancer** represents a frequent malignancy both in men and women. The **transabdominal ultrasound** aspect of an antral neoplasm is that of a hypoechoic gastric wall thickening, with obliterated layers. The wall may reach 10-15 mm or even 20 mm in thickness. The thickening might be even or uneven. Assessment of gastric wall thickness (especially antral) will be performed through sagittal sections. The tumoral stomach in this section looks like a “target” lesion. Because of tumoral invasion, the gastric lumen appears narrowed, revealing the ultrasound aspect of malignant stenosis. Gastric emptying insufficiency (delayed gastric emptying) by pyloric stenosis represents one of the easiest ultrasound diagnoses. Ultrasound characteristics of benign pyloric stenosis are thin antral walls, with normal structure.

Malignant pyloric stenosis is associated with thick antral walls, anfractuous and hypoechoic.

The small intestine is a segment of the digestive tract subject to difficult paraclinical evaluation. Under these circumstances, ultrasound examination in enteric pathology is a tempting alternative. It requires an experienced examiner and a high-performance ultrasound machine, with 3.5 MHz, 5 MHz, and possibly 10 MHz (sector or linear) transducers. **Intestinal obstruction: the ultrasound appearance** of an intestinal obstruction consists of dilated intestinal loops upstream of the obstruction, which are filled with liquid. The “hydric level” can be very well visualized by ultrasound, the air being situated above the liquid level. In general, a very intense peristaltic activity of the intestinal loops can be visualized (in dynamic ileus). Inside the dilated loop, an anechoic fluid or, more frequently, intestinal chyme (a semi-solid structure containing particles in brown motion) will be seen. In the presence of an ultrasound picture of intestinal obstruction, it will be attempted to establish the site of obstruction. The dilated loop will be explored until the site is discovered. **Crohn’s disease** is an inflammatory disease of unknown origin that can affect every part of the digestive tract. **The ultrasound appearance** in terminal ileitis is characterized by an obvious thickening of the terminal ileum wall, up to 10-15 mm (normal thickness is 3-4 mm), without a clear delimitation between the wall layers. There is a segmental narrowing of the lumen over several centimeters, with its upstream dilatation. An anechoic inflammatory exudate in the proximity of the pathological loop can sometimes be evidenced. For an experienced ultrasonographer, the diagnosis of a severe complication such as stenosis or fistulization (e.g. in the urinary bladder) is possible. Ultrasound will be aimed at assessing potential colonic lesions, considering that these may also occur in Crohn’s disease. **The appendix:** in current clinical practice, the diagnosis of acute appendicitis is quite easy, starting from a suggestive clinical picture, along with leukocytosis. In about 30% of the cases, acute pain has an atypical location or radiation, symptoms can be mild, and leukocytosis can be at the limit. In these situations, a correct diagnosis is imperative: is this or is this not acute appendicitis? Ultrasound may be a diagnostic means for the experienced examiner.

„Victor Babeș” University of Medicine and Pharmacy,
WFUMB Center of Education, Regional Center of Research
in Advanced Hepatology, Academy of Medical Science,
Timișoara, Romania



Experience in appendicular ultrasound is achieved by clinical, imaging, and surgical correlations.

For the ultrasound detection of the appendix, the right flank is scanned downwards, while sliding the probe along the ascending colon and cecum (hyperechoic structures through the contained air), using a 5-10 MHz multi-frequency linear transducer. At the end of the cecum, the appendix will be evidenced. The appendix is easier to be seen in pathological situations, compared to cases when it is normal. A normal appendix has an outer diameter of up to 6 mm and walls of up to 2 mm thick. For teams trained for the ultrasound visualization of the appendix, this is possible in up to 50-70% of cases, under normal conditions.

The ultrasound appearance in acute appendicitis is characterized by an appendicular diameter greater than 6 mm or the visualization of an appendicolith. The inflamed appendicular wall will be thickened through edema and stratification will disappear. The inflamed appendix in the transverse section will have a “target” appearance. The presence of an inflammatory fluid reaction around it may be evidenced.

The colon: the last portion of the digestive tract, the colon, can benefit from the diagnostic contribution of transabdominal ultrasound. It is recommended that on abdominal ultrasound examination, the colic frame should be scanned, which sometimes allows finding a “target” lesion along the colon tract, suggesting a colon tumor. *The ultrasound appearance* of a colon tumor is “target-like” or “kidney-like”.

In ulcerative colitis (UC): if the normal colon wall is 3-4 mm thick when affected by UC, the colon wall reaches a thickness of up to 6-10 mm. A hypoechoic thickening of the inner layer (mucosa and submucosa) occurs. In general, the stratification of the colon wall is preserved. In the diagnosis of ulcerative colitis, a transabdominal ultrasound examination will start from the rectum upwards, and the site up to which there are pathological changes in the colon, from where the appearance of the colon becomes normal, will be observed. In this way, the form of UC will be evaluated: proctosigmoiditis left colitis, or pancolitis.

In the case of ulcerative colitis (UC), lesions are continuous, while in Crohn’s disease lesions are segmental. In Crohn’s disease, there is a transmural involvement of the wall, with the disappearance of stratification, while in UC stratification of the wall is kept for a long time.

Diverticulitis is an inflammatory process situated at the level of a colon diverticulum. Diverticulosis is a common disorder, but its complications such as diverticulitis or diverticular bleeding are rare. In the presence of clinical suspicion of diverticulitis, *ultrasound* can be the first evaluation method. It will demonstrate a hypoechoic area (the inflamed diverticulum) in contact with the colon, which usually contains air. The size of the hypoechoic area is usually 1-4 cm, but in the case of an abscess, it can be even larger. The pressure of the ultrasound probe on that area induces intense pain. In case of an unclear ultrasound diagnosis or a suspicion of diverticular abscess, an investigation by CT is necessary. In the suspicion of a diverticular abscess, using CEUS can reveal inflammation or collection.

In conclusion, we wish to mention that the ultrasound of the digestive tract (GIUS) has an informative purpose for beginners, but can become part of clinical practice for the experienced ultrasonographer.

Recently, EFSUMB (European Federation of Societies for Ultrasound in Medicine and Biology) produced many Guidelines and practical recommendations for the use of gastrointestinal ultrasound (GIUS). The first part is how to examine the digestive tube using transabdominal ultrasound. The second is about the use of GIUS for the diagnosis of inflammatory bowel disease. The next Guideline is about the use of GIUS for inflammatory conditions (diverticulitis and appendicitis). Reading these guidelines, the practitioners that like to be skilled in this field can have more information on this topic (www.efsumb.org).

THE ROLE OF ARTIFICIAL INTELLIGENCE IN THE COMPLEX EVALUATION OF PATIENTS WITH LIVER STEATOSIS

Prof. Dr. Adrian Saftoiu PhD, MSC, AGAF, FASGE

Professor UMF Craiova
Assoc. Professor Copenhagen, Denmark
Professor of Diagnostic & Therapeutic Techniques in Gastroenterology
Gastroenterology Dept Ponderas
EFSUMB Former President



Gheorghe Elena Codruta MD PhD

Fatty liver disease has slowly turned into a "silent pandemic" in recent years, with a global prevalence of approximately 25%.

The non-invasive diagnosis of liver steatosis includes a combination of ultrasound, serum markers, and clinical scores but their performance is limited compared to liver biopsy.

However, artificial intelligence (AI) is gaining more and more ground in the medical field through the excellent performance it has demonstrated in various applications.

In particular, deep learning (DL) techniques such as convolutional neural networks (CNNs) have been used in the past 5 years in radiology and histopathology for extracting diagnostic and prognostic information.

These applications include an automatic imaging diagnosis of liver steatosis as well as automatic detection of liver fibrosis, the objective quantification of hepatic steatosis, and the differentiation of microvesicular steatosis from macrovesicular steatosis, etc. Nevertheless, future studies and technologies must find the missing link between AI applications and their implementation in daily clinical practice.

FOCUS (FOCUSED CARDIAC ULTRASOUND) AND BASIC CARDIAC ULTRASOUND FOR NON-CARDIOLOGISTS

Dr. GERGELY Agoston

MD, Vice president of the WG of the Hungarian Association of Cardiovascular Imaging, the HIT Ambassador of Hungary, Member of the Web and Communication Committee of the EACVI, Nucleus member of the ESC Editors Network, Associate Editor of *Cardiologia Hungarica*



Ultrasound for visualizing the cardiovascular system and lung is an exceptionally versatile and powerful modality. Advances in the development of ultrasound machines allow high-quality, portable, and low-cost imaging, making optimal circumstances for the FOCUS. Being able to rapidly diagnose cardiac pathologies at the bedside

is a promising and valuable opportunity for the users of primary care. The general diagnostic power of echocardiography is strong; however, adequate interpretation in certain clinical situations is essential to reduce the likelihood of potential diagnostic and treatment errors.

Therefore, having a set of standards for optimal education and training and to identify the levels of competence are essential. FOCUS examination is aimed to detect a limited number of critical cardiac conditions, and may provide relevant clinical information regarding pericardial effusion, left and right ventricular size and function, gross valvular abnormalities and intravascular volume status. A rational supplementary diagnostic utility is lung ultrasound, which often helps in the differential diagnosis of dyspnea. The presentation gives an illustrated overview of the theoretical and practical features of basic FOCUS, highlighting the importance of education, training and levels of competence

SONOGRAPHY IN EMERGENCY AMBULANCE SERVICE

Dr. Peter SIGMUND

MD, Präsident der
Steirischen Akademie für
Allgemeinmedizin



There are several situations in the emergency ambulance service where sonography is very useful.

Four scenarios where ultrasound - already at a prehospital stage - can make a significant difference:

- **Dyspnea**
- **Resuscitation**
- **Trauma**
- **Shock**

The evident indications deliver potential consequences for therapy and transport. The presentation will demonstrate the processing of crucial emergency scenarios with sonography.

1.POCUS (POINT OF CARE SONOGRAPHY) IN GENERAL MEDICINE.

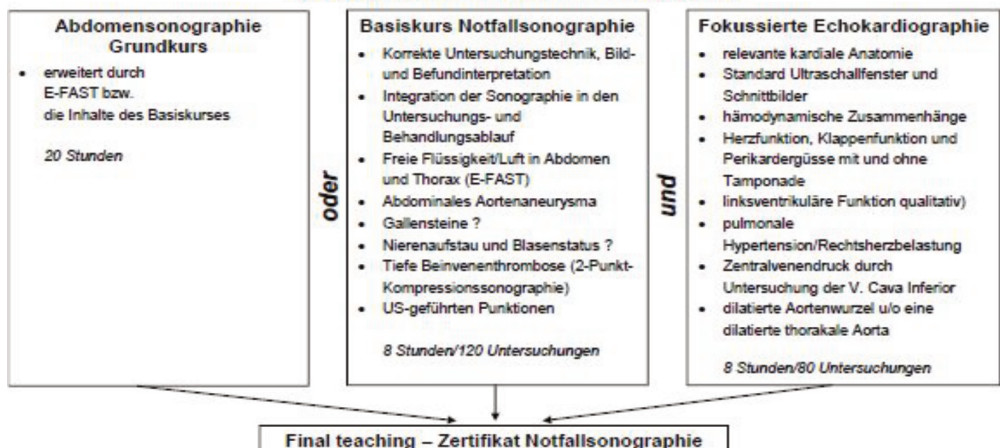
Dr. Peter SIGMUND
MD, Präsident der Steirischen Akademie
für Allgemeinmedizin

The use of sonography in general medical practice and its integration into the physical examination of the patient can considerably increase diagnostic value and accuracy. Point of Care Sonography aims at swift answers to medically relevant yes-no questions in contrast to in depth sonographic examinations by various medical specialists.

In primary health care both anamnesis and physical examination often raise further clinical issues. Focusing on the patient's specific problems these can be shaped into sonographic yes-no-questions: Gall bladder portrayable and without stones? Full urinal bladder? Congested renal pelvis? Dilated abdominal fluid? Intestinal motility? Spleen visible, of normal size? Intrauterine contents? Dilated abdominal aorta? Pleural effusion? Interstitial lung fluid? Pneumothorax? Congested vena cava, hepatic veins? Venous thrombosis? Normal heart function? Soft-tissue swelling solid/liquid?

The sonographic findings can then be interpreted in their clinical context. This multidisciplinary use of sonography is the topic of the training concept 'Emergency Sonography', a curriculum that has been developed by the Societies for Ultrasound in the German speaking countries DEGUM/ÖGUM/SGUM since 2010 and allows a basic education in emergency ultrasound which is also viable for practicing doctors.

Notfallsonographie-Basisausbildung



SYNDROME-FOCUSED ULTRASONOGRAPHY

Dr. Mateusz KOSIAK

Co-founder EDUSON

The idea of the lecture is to present the usefulness of sonographic examination performed by primary physicians in patients with non-specific clinical symptoms (dyspnoea, haematuria, back pain, abdominal pain, etc.). It is important to present the usefulness of sonographic examination in different areas of the body - "from head to toe". Each time the primary physician would like to perform "syndrome-focused ultrasonography" she/he needs to be prepared for unexpected findings, which are not related to the presented symptoms but require further diagnosis. That's why physicians who perform "syndrome-focused sonography" must be familiar with a wide range of sonographic images, as well as with the limitations of the examination.

It is not unusual that more than one pathology may be found during the sonographic examination. In those cases, the role of primary physicians is not only to detect pathologies but, considering the medical history and physical examination, to find the pathology that is responsible for the symptoms.

THORACIC ULTRASOUND

Dr. Mateusz KOSIAK

Co-founder EDUSON



Thorax, from a sonographic point of view, can be divided into three areas: chest wall, pleural effusion, and lung sonography.

The idea of the lecture is to present a wide range of sonographic images that can be found in the areas that are mentioned above.

Starting from the chest wall for example lipoma, abscess, metastatic lesions, and a broken rib. Going through pleural effusion: assessing volume and differentiating between exudate and transudate.

Finally, going to lung sonography: pneumonia, lung edema, pneumothorax. It is important to underline how primary physicians can benefit from thoracic ultrasound examination in various clinical situations.

INTRODUCTION TO THYROID CLINICAL ULTRASOUND

Prof. Dana Stoian MD, PhD, Dr Sc, FECMS, CCD
Department of Endocrinology, Department of Internal Medicine II, Victor Babes
University of Medicine Timisoara, Romania



It is well known that thyroid ultrasound is considered the 1st line morphological evaluation tool. Thyroid screening is not recommended universally, but the procedure is important to be known by a vast majority of general practitioners, since more than 50% of the adult populations is described with thyroid nodular disease, iodine deficiency disorders do affect more than 20% of the adult population, around the globe and the prevalence of autoimmune variant of thyroid disease is increasing affecting around 20% of the adult female population, never the less many drugs such as lithium, Tyrosinase inhibitors, Amiodarone and immunotherapies (Check point inhibitors) do associate different types of thyroid impairment.

The general accepted indications of thyroid ultrasound, according to the American Thyroid Association (ATA), American Association of Clinical Endocrinology (AACE) and ESE (European Society of Endocrinology) are thyroid screening, evaluation of anatomical integrity, presence of nodular disease, characterisation of nodular diseases, evaluation of the presence and characteristics of adenopathy's, first line approach in the coexistence of thyroid and parathyroid disease.

Ultrasound can diagnose the absence of thyroid in the normal position, thyroid agenesis being confirmed by the lack of thyroid activity in scintigraphic evaluation; lobar agenesis, hemi lobar agenesis; presence of pyramidal lobe or of accessory lobe.

The general thyroid evaluation comprises the measurement of the volume, the evaluation of echogenicity, omogeneity and vascularisation of the parenchyma, regardless the presence or absence of nodules. Increased volume is suggestive for Iodine deficiency, active (Hashimoto variant) if autoimmune thyroid disease or active phase of Graves' disease or aggression thyroiditis. Decrease volume is suggestive for thyroid atrophy observed in end stage autoimmune thyroid disease, end stage of aggression thyroiditis, after exposure to radioactive iodine or external radiations.

The echogenicity is dependent on the iodine intake, conditioning the colloid component of the thyroid, fibrosis, such as in autoimmune cases, severity of the disease. Evolution of the echogenicity can be used as a predictor of disease evolution: cure of Graves/ aggression thyroiditis - normalisation of echogenicity, decreasing of echogenicity being suggestive for worsening of Graves, subacute thyroiditis, or chronic autoimmune disease. The same is valid for vascularisation, which has to be considered an evolution marker on Graves, Autoimmune and aggression thyroiditis.

In thyroid nodular disease we use different risk stratification models, to have a correct identification of risk nodules, with a higher probability of thyroid cancer, with the aim of reducing the number of unnecessary biopsies or diagnostic surgeries. The most important features evaluated, respectively suggestive for malignancy are consistency (solid), shape (taller than wide), margins (ill defined), echogenicity (hypoechoic), omogeneity (inhomogeneous), posterior phenomenon (lack/attenuation), position (subcapsular), integrity of the capsule (interrupted), presence of calcifications (coarse, intranodular), presence of adenopathy (altered shape, loss of hilum).

There is no consensus which TIRADS model to be used, since there are many well documented ones, but the most frequent used ones are the European TIRADS and the ACR TIRADS. Active prospective use of one model is recommended, to have a uniform evaluation of the patients. Using thyroid ultrasound in daily practice means screening of the general population, evaluation of the individual risk (1 case of a thyroid nodule) or having parameters to evaluate the course of the disease, in cases of Graves, autoimmune or aggression thyroiditis.

INTRODUCTION TO DUCTAL AND CONVENTIONAL BREAST CLINICAL ULTRASOUND.

Prof. Dana Stoian MD, PhD, Dr Sc, FECMS, CCD
Department of Endocrinology, Department of Internal Medicine II,
Victor Babes University of Medicine Timisoara, Romania



According to EUSOBI, the ultrasound evaluation of the breast, regardless technique is currently use in following situations: palpable breast mass, axillary lymph node, mamelon discharge, nipple retraction of recent onset, first evaluation in pregnant women, in breastfeeding women, and in women aged below 40, or women with breast implants.

It is used to characterise nodules observed by MRI or mammography, nodules developed on previous scars, respectively to guide the biopsy. In the absence of MRI, ultrasound cand be used to screen the high-risk women, aged below 35, to monitor breast cancer cases or to determine the stage of the disease.

Mammographic dense breast screening, in women over 40 years of age, follow of breast cancer cases occult on mammography, screening of breast in incidental mastodynia are considered as possible indications of the ultrasound use.

Ductal breast approach representant an anatomical approach using radial scanning as the focus technique. This technique allows the operator to visualise all layers observed in the normal anatomy of the breast, with nipple and skin as the main landmarks for positioning and measurements.

Antiradial scanning is used complementary to the radial approach, only o defined lesions, to differentiate normal structures versus focal lesions, respectively complete the measurement and the evaluation.

In the presence of a focal lesion, regardless the used approach (radial or sagittal) the complete evaluation must be made regarding consistency, echogenicity, shape, dominant axis, margins, homogeneity, posterior phenomenon, vascularisation, position, integrity of the surrounding structures, skin aspect, Cooper ligament shape, unique lesion, multifocality versus multicentricity, respectively the characteristics of axillary lymph nodes.

The final report is according to the BIRADS lexicon.

INTRODUCTION TO ULTRASOUND-BASED ELASTOGRAPHY



Prof. Vito Cantisani, MD, PhD.

Assoc. Prof. of Radiology, Vice-Dean of Medicine and Dentistry, Univ. Sapienza, Rome, Chairman of Ultrasound Unit Policlinico Umberto I, Univ. Sapienza, Rome, SIUMB President, EFSUMB Honorary Treasurer, Editor of *Ultraschall EJU*, *UiO*, Qualified as Full Prof in Radiology at ASN, [<https://web.uniroma1.it/droap/>](https://web.uniroma1.it/droap/)

The mechanical properties sensed by palpation and elastography are associated with the elastic restoring forces in the tissue that act against a type of deformation (shape change) known as shear.

Elastography uses ultrasonic imaging to observe tissue shear deformation in a real-time two-dimensional image sequence, after applying a force that is either dynamic (e. g. by thumping or vibrating) or varying so slowly that it is considered “quasi-static” (e. g. by probe palpation). The deformation may be represented in an elasticity image (elastogram), or as a local measurement, in one of three ways:

1. tissue displacement may be detected and displayed directly, as in the method is known as acoustic radiation force impulse (ARFI) imaging;
2. tissue strain may be calculated and displayed, producing what is termed strain elastography (SE);
3. in the dynamic case only, the data may be used to record the propagation of shear waves, which are used to calculate either a) regional values of their speed (without making images) using methods referred to herein as transient elastography (TE) and point shear-wave elastography (pSWE), or b) images of their speed using methods referred to herein as shear-wave elastography (SWE) which includes 2 D SWE and 3 D SWE. These shear-wave speed methods could all be grouped under the term SWE.

In ultrasonic imaging, a varying pressure at the tissue surface causes a change in density, and both perturbations travel together as a longitudinal wave. Its speed (about 1540 ms⁻¹), is determined almost entirely by the tissue’s density and the bulk modulus of elasticity.

The shear deformation of the return echo of the US beam is therefore determined by the biomechanical properties of the analyzed tissue, displaying information about their composition.

Elastosonography currently has been applied in the evaluation of focal lesions of multiple parenchymal organs such as thyroid and breast, but also in the evaluation of diffuse pathology of the hepatic parenchyma or the soft musculotendinous components.

Recently EFSUMB and WFUMB produced Evidence-Based Guidelines which provide recommendations and limitations of USE clinical use.

STRAIN ELASTOGRAPHY AS A USEFUL TOOL IN DAILY PRACTICE

Prof. Vito Cantisani, MD, PhD.

Assoc. Prof. of Radiology, Vice-Dean of Medicine and Dentistry, Univ. Sapienza, Rome, Chairman of Ultrasound Unit Policlinico Umberto I, Univ. Sapienza, Rome, SIUMB President, EFSUMB Honorary Treasurer, Editor of *Ultraschall EJU*, *UiO*, Qualified as Full Prof in Radiology at ASN, [<https://web.uniroma1.it/droap/>](https://web.uniroma1.it/droap/)



US-Elastography (USE) may be considered as a type of remote palpation that allows measurement and display of biomechanical properties associated with the elastic restoring forces in the tissue that act against shear deformation. Different types of elastography obtain the same underlying information, associated with the shear elastic modulus defined below. Shear deformation is generated by a force applied to a single location or broadly across the body surface. Significantly, transient shear deformations will propagate as shear waves.

Strain elastography, although it remains the most widely implemented elastography method on commercial systems, is the least used method for the liver. As motion occurs due to either palpation with the ultrasound probe or to physiological motion, images of axial displacement between sequentially acquired ultrasound echo images are calculated using either radiofrequency echo correlation tracking or Doppler processing (when Doppler processing is used the method is often called strain rate imaging). A moving window axial-gradient estimator converts the axial displacement images to strain images.

Little has changed concerning the available systems, artefacts and advantages and disadvantages of strain imaging, although the trend is towards increased robustness, using more frame and pixel quality selection methods, and increased sensitivity allowing useful elastograms to be obtained with little or no palpation, relying on involuntary hand motions or physiological motion, on some systems.

A robust scientific evidence supports the use of SE in the evaluation of the nodule differentiation of Breast, Prostate, Thyroid, Pancreas, kidney, testis and for Bowel, spleen, Lymph Nodes, and Musculo-Skeletal disorders assessment, while its application in focal and diffuse liver disease is not currently recommended, since SWE have shown more diagnostic accuracy. The SE versatility, ease of use and quantity of information provided make it currently considered one of the most useful and promising tools in the multiparametric integration of routine ultrasound examination. Herein, recommendations, limitations and tips and tricks of Strain-USE for thyroid, breast and testis evaluations will be presented.

AI ROLE IN OBTAINING CARDIAC ASSESSMENT PARAMETERS: A CASE DEMONSTRATION DURING A ROUTINE VISIT TO THE PRIMARY CARE CLINIC

Vaigast S., Binenbaum M., Evron, I, Polliack G., Zicherman Y., Chadi B
Triso Technologies, Ishi, Israel



The Case: A 50-year-old man presented to the primary care physician (PCP) with complaints of recent onset of shortness of breath and fatigue. On examination, heart sounds as heard via the stethoscope are normal. Other parameters: Blood pressure 103/68 mm Hg, heart rate 80 beats/min, respiratory rate 14 breaths/min and weight 83 kg.

When implementing an Artificial Intelligence (AI) application on the PCP's ultrasound probe (AI -Triso Technologies, Device - Phased Array probe by Terason), mildly enlarged Right Ventricle (RV) is demonstrated clearly on the Sub-Costal (Subxiphoid) 4 Chamber view, compared to the Left Ventricle (LV). The Sub-Costal IVC view shows a dilated IVC and mild IVC collapse. Apical 4 Chamber view presents a small apical pericardial effusion together with an enlarged RV. Both Apical 4 Chamber and 2 Chamber views demonstrate a normal Ejection Fraction (EF).

Findings are summarized in the AI's final report, while the physician is able to watch the traced LV and RV in the recorded clips and watch the AI's confidence level.

Throughout the examination procedure, the AI ranks the attained views as well as the pictures' quality. When moderate-to-good views are obtained, the AI calculates automatically and in real-time, cardiac parameters, such as Ejection Fraction, Cardiac Output, RV/LV, IVC size, IVC Collapse Rate and Pericardial Effusion. A Final report is presented and the complete procedure is archived and saved for further analysis and workup.

Based on these findings, the PCP decides to refer the patient to further cardiology investigation - full Trans Thoracic Exam (TTE) and possibly cardiac CT.

Summary: A small echo-device that is supported by AI app., enables a clinician who is not an echo cardiographer, to perform a point of care echo scan, attaining appropriate anatomical views as well as relevant quantitative cardiac parameter values for providing a practical decision support tool to the necessity of further investigation. The procedure is completed within the time frame in accordance with the PCP routines. Additional research might be required for assessing the adequacy of this procedure in supporting referral decisions.



MODULE 10: ULTRASONOGRAPHY AND MEDICAL IMAGING

I. Specific objectives

At the end of this training module in medical ultrasonography and imaging, the resident physician will be able to:

- knows how to choose the appropriate ultrasonographic technique (transducer, section, equipment setting, technique).
- knows how to make a quick emergency diagnosis, using the ultrasonographic result
- participates in the formulation of an ultrasound bulletin, supervised by the training manager.
- integrate the obtained ultrasonographic information and other imaging investigations in the clinical context of the patient
- identify the need to request an imaging investigation (knowledge of indications and contraindications and the opportunity to perform them)

II. Course topics adapted to specific objectives

1. Imaging investigation methods. Conventional radiology, sectional radiology, computed tomography, nuclear magnetic resonance MRI (techniques, principles, general indications, limitations, advantages, disadvantages)
2. Basic principles of ultrasonography (definition, the physical basis of the method, equipment, techniques, procedures, general indications, limitations).
3. Ultrasonographic elementary semiology (normal, pathological). (obtaining an optimal ultrasound image: recognition criteria, methods of achievement; standard ultrasonographic sections and plans)
4. Ultrasonography in upper abdominal pathology (liver, gallbladder, pancreas, spleen)
5. Ultrasonography in the pathology of the middle abdominal floor (digestive tract, retroperitoneal space)
6. Ultrasonography in the pathology of the lower abdominal floor (bladder, prostate, uterus, ovaries).
7. Ultrasonography of the cervical region (lymphadenopathy, thyroid pathology, carotid atheromatous, cervical masses)
8. Ultrasonography with special applications: musculoskeletal, heart, pregnancy
9. Ultrasonography in medical and surgical emergencies.
10. Senological ultrasonography
11. Ultrasound examination of the digestive, respiratory, cardiovascular, and mediastinal, reno-urinary and pelvis, breast, and osteoarticular system. Imaging techniques (other than ultrasonography), procedures, general indications, limitations
12. Multimodal ultrasonography in clinical practice. Definition, principle, main clinical indications, preparation for examination, benefits, and risks of examination

III. Themes of practical activities

1. Physical and technical principles of ultrasound. Introductory notions - the principle of the method, equipment, terminology, and the principle of interpreting images. Artifacts in two-dimensional ultrasound: causes, description, elimination methods
2. Introductory notions, principles, equipment, terminology, artifacts
3. Practical elementary ultrasound semiology. Ultrasound standard sections and plans. Ultrasound examination indications. Preparing the patient for various ultrasound examinations
4. Ultrasound equipment in the family doctor's office. Ultrasound applications of Point of Care Ultrasonography - PoC - US pathology and medical emergencies
5. Applications of ultrasonography in the pathology of the upper abdomen - liver, gallbladder, pancreas, and spleen US exam in primary healthcare.
6. Applications of ultrasound in the pathology of the middle and lower abdomen - kidneys, adrenal glands, retroperitoneal space, and pelvis
7. Applications of clinical ultrasonography in medical-surgical emergencies. Clinicoimaging correlations
8. Ultrasound of the prostate and urinary tract in primary medicine
9. The physical basis of Doppler techniques. Ultrasonography in visceral and peripheral vascular emergencies
10. Rapid cardiac evaluation in the family doctor's office
11. Introductory elements of ultrasound in pediatrics
12. Applications of ultrasound in thyroid, breast, obstetrics, and gynecology pathology in the practice of the family doctor
13. Interpretation of the ultrasound examination and its integration in a clinical context.

FEEDBACK QUESTIONNAIRE



UNION EUROPÉENNE DES MÉDECINS SPÉCIALISTES
EUROPEAN UNION OF MEDICAL SPECIALISTS
Association internationale sans but lucratif International non-profit organisation

RUE DE L'INDUSTRIE, 24
BE- 1040 BRUSSELS
www.uems.eu

T +32 2 649 51 64
F +32 2 640 37 30
info@uems.eu

EACCME® participant's evaluation form

1) Quality of the event

How useful for your professional activity did you find this event?

Extremely useful	Useful	Fairly useful	Not useful

If this activity was not useful, please explain why:

What was your overall impression of this event?

	Excellent	Good	Fairly good	Poor	Very poor
Programme					
Organisation					

What was the best aspect of this event?

What was the worst aspect of this event?

2) Relevance of the event

Did the event fulfil your educational goals and expected learning outcomes?

Very much	Somewhat	Not much	Not at all	Undecided

Was the presented information well balanced and consistently supported by a valid scientific evidence base?

Very much	Somewhat	Not much	Not at all	Undecided

How useful to you personally was each session?

	Extremely useful	Useful	Fairly useful	Not useful	Undecided/ DNA
1 st session's title					
2 nd					

PRESIDENT: DR ROMUALD KRAJEWSKI
TREASURER: DR BERNARD MAILLET

SECRETARY-GENERAL: PROF VASSILIOS PAPALOIS
LIAISON OFFICER: DR ZLATKO FRAS

3) Suitability of formats used during the event

Was there adequate time available for discussions, questions & answers and learner engagement?

Yes, always/almost always	Yes, sometimes	Only rarely	Never	Undecided

Can you indicate any innovative elements during the activity?

.....

4) Ways the event affects clinical practice

Will the information you learnt be implemented in your practice?

Very much	Somewhat	Not much	Not at all	Undecided

Can you provide ONE example how this event will influence your future practice?

.....

5) Commercial bias

Did all the faculty members provide their potential conflict of interest declaration with the sponsor(s) as a second slide of their presentation?

Yes, all	Yes, for the majority	Yes, but only a small part	No	Undecided/ don't know

Can you provide an example of biased presentation in this activity?

.....

Do you agree that the information was overall free of commercial and other bias?

Strongly agree	Rather agree	Rather disagree	Strongly disagree	Undecided/ don't know